

McGLAMRY'S COMPREHENSIVE
TEXTBOOK OF

FOOT AND ANKLE SURGERY

ALAN S. BANKS

MICHAEL S. DOWNEY

DENNIS E. MARTIN

STEPHEN J. MILLER



VOLUME 1

THIRD EDITION



LIPPINCOTT WILLIAMS & WILKINS

Mau and Ludloff Osteotomies

Tzvi Bar-David and Paul M. Greenberg

HISTORY

In 1913 and again in 1918, Ludloff described an oblique first metatarsal osteotomy oriented from dorsal proximal to plantar distal for the correction of metatarsus primus abductus associated with hallux abducto valgus deformity (1,2). In 1926, Mau challenged the stability of the Ludloff procedure and described the reverse osteotomy oriented from plantar proximal to dorsal distal, thereby creating a dorsal shelf to resist weight-bearing forces (3) (Figs. 24 and 25). As originally described, fixation was not applied to these osteotomies, despite their inherent instability. The middiaphyseal location of each procedure was also a potential concern relative to bone healing. Therefore, both these osteotomies were largely rejected for several decades. However, partly because of technical modifications and the advent of stable forms of fixation, these procedures have gained popularity and are most commonly employed as alternatives to closing base wedge osteotomies (4–8).

At first glance, these procedures may appear to be almost identical. However, to appreciate the difference between each osteotomy fully, it is important to discuss the concept of planes of motion. Conceptually, two types of osteotomies provide correction of an increased intermetatarsal angle: wedge resection and plane-of-motion osteotomies.

In a wedge resection procedure such as the closing base wedge osteotomy, the hinge axis influences the direction of motion (9). In a plane-of-motion osteotomy, there is no hinge; therefore, the direction of motion is influenced by the plane or orientation of the osteotomy (10). Plane-of-motion

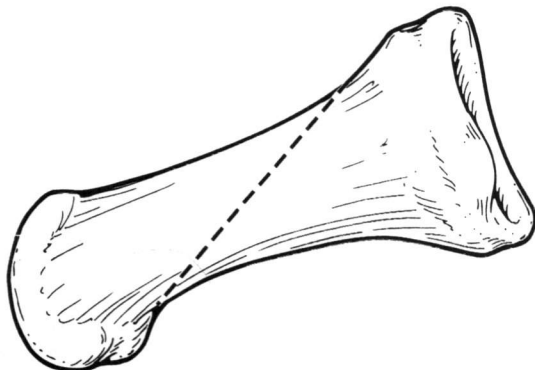


FIG. 24. The Ludloff osteotomy. Lateral view of the first metatarsal.

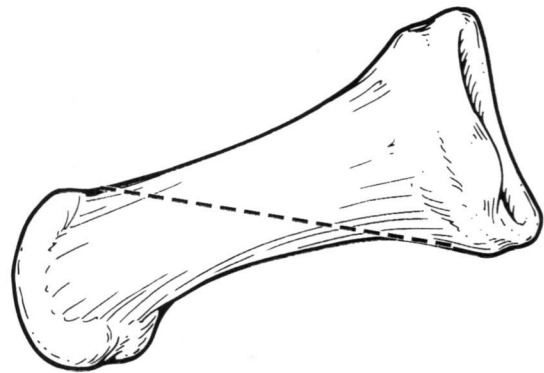


FIG. 25. The Mau osteotomy. Lateral view of the first metatarsal.

osteotomies may be either transpositional or rotational. In a transpositional osteotomy, such as the Ludloff procedure, one bone fragment is slid on the other, to create areas without bone-to-bone contact. Other examples include the Austin, offset-V, and Scarf procedures. In a rotational osteotomy, such as the Mau procedure, the distal portion of the metatarsal is rotated or is pivoted around a relatively fixed axis. Therefore, the essential differences between the Mau and Ludloff procedures are the orientation of the osteotomy and the means by which correction is achieved (Fig. 26).

INDICATIONS

Both the Ludloff and Mau procedures are indicated for correction of hallux abducto valgus deformities with intermetatarsal angles greater than 13 degree and are alternatives to a closing base wedge osteotomy (8,11). Generally speaking, correction may be achieved with relatively little shortening of the first metatarsal (4). Therefore, these procedures may be useful in patients with a short first ray. There are no age limits, and each procedure has been performed on patients in their seventh decade. As with any proximal osteotomy, one must be cautious in children with open growth plates. The average intermetatarsal angle reduction has been reported between 6.5 and 10.5 degrees (4–6), but good correction of deformity has been noted even in patients with first intermetatarsal angles up to 20 degrees (4,6). Important factors are the quality of the bone and the ability of the patient to remain non-weight bearing postoperatively. The

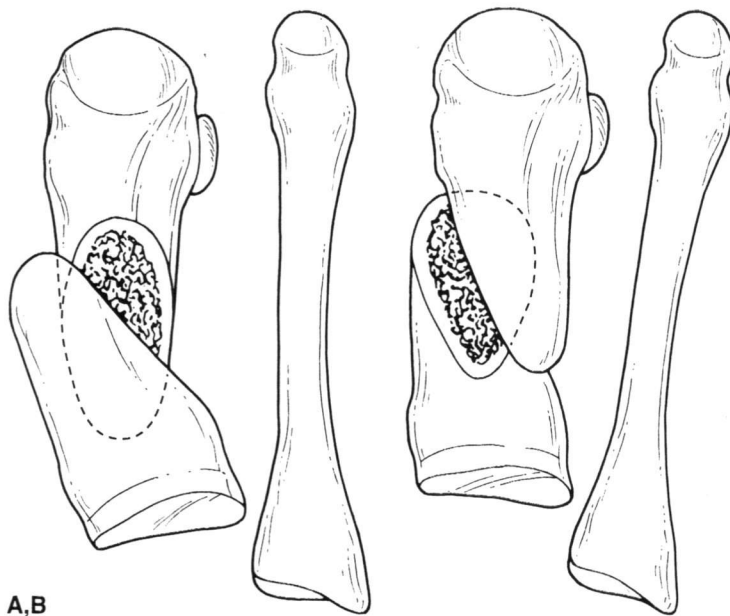


FIG. 26. A: The Mau procedure is a rotational osteotomy, and the fragments are rotated. **B:** The Ludloff procedure is a transpositional osteotomy, and the fragments slide on each other.

osteotomies are simple to perform, versatile, and easily adjusted intraoperatively.

Because the Mau is a rotational osteotomy and bone-to-bone contact is maintained proximally, troughing and accompanying instability are not common problems. Troughing may be more likely with the Ludloff procedure because the operation is transpositional. However, there may be a significant area of cortical overlap at the proximal and distal aspects of the osteotomy to promote stability.

OPERATIVE TECHNIQUE

Mau Osteotomy

A dorsolateral incision the length of the first metatarsal is placed medial and parallel to the extensor hallucis longus tendon. The incision is deepened bluntly to the periosteum, and the capsule of the first metatarsophalangeal joint is released. The periosteal incision is then extended proximally, and the metatarsocuneiform joint is identified. The periosteum is reflected dorsally and plantarly, and the plantar flare of the base of the metatarsal is visualized. Care is taken not to disrupt the plantar first metatarsocuneiform ligament because this provides sagittal plane stability to the first ray (12) (Fig. 27).

The foot is rotated laterally to enhance the visualization of the dorsal, medial, and plantar surfaces of the metatarsal. A power saw is used to perform the osteotomy, which is oriented from distal dorsal to proximal plantar. The cut extends from approximately 1 to 1.5 cm proximal to the metatarsophalangeal joint to approximately 1 to 1.5 cm distal to the metatarsocuneiform joint. The entire length of medial cortical bone is osteotomized first, and the medial cortex is then used as a guide for cutting the lateral cortex.

The osteotomy is stabilized with a bone clamp before any manipulation. A 0.045-inch Kirschner wire is then drilled

perpendicular to the osteotomy from dorsal to plantar in the proximal aspect of the metatarsal. The purpose of the wire is to act as an axis of rotation for the osteotomy. Once the Kirschner wire is inserted, the bone clamp is removed, and the distal fragment is rotated laterally to reduce the intermetatarsal angle. The bone clamp is then reapplied to stabilize the osteotomy in its corrected position (Fig. 28).

The intermetatarsal angle is evaluated before fixation to determine the amount of reduction. One may use the juxtaposition between the first and second metatarsal heads as a general guide to gauge the degree of correction. If insufficient or excessive correction is deemed to have occurred, then the bone clamp may be removed and the osteotomy realigned into a better position. The osteotomy is fixated, and the medial overhang of bone is removed (Figs. 29 and 30).

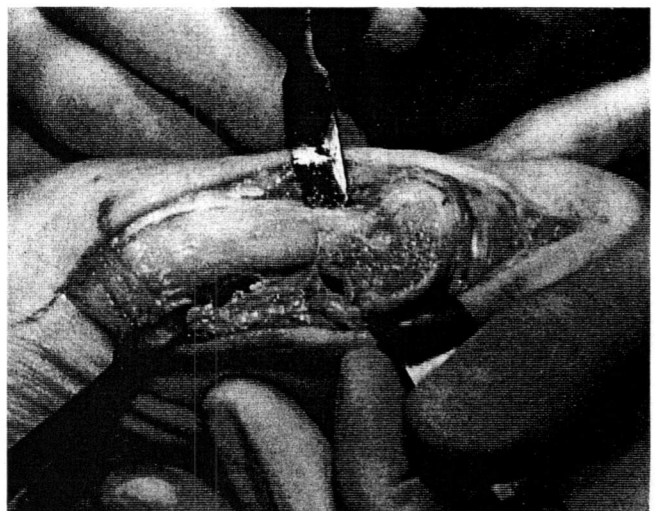


FIG. 27. Intraoperative photograph demonstrating the exposure required to effect the Mau osteotomy.

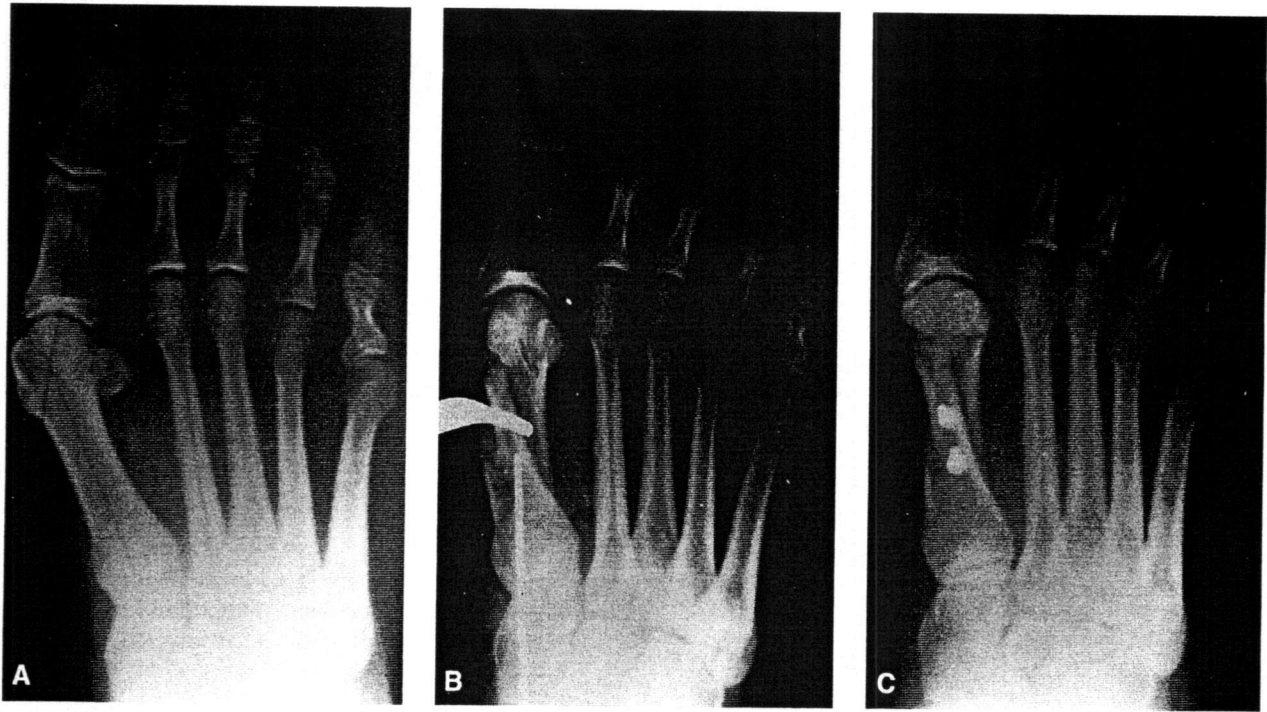


FIG. 28. **A:** Preoperative radiograph of a patient with hallux abducto valgus deformity. **B:** Intraoperative radiograph after the Mau osteotomy. Note the Kirschner wire, used as an axis for rotation. **C:** The osteotomy after fixation.

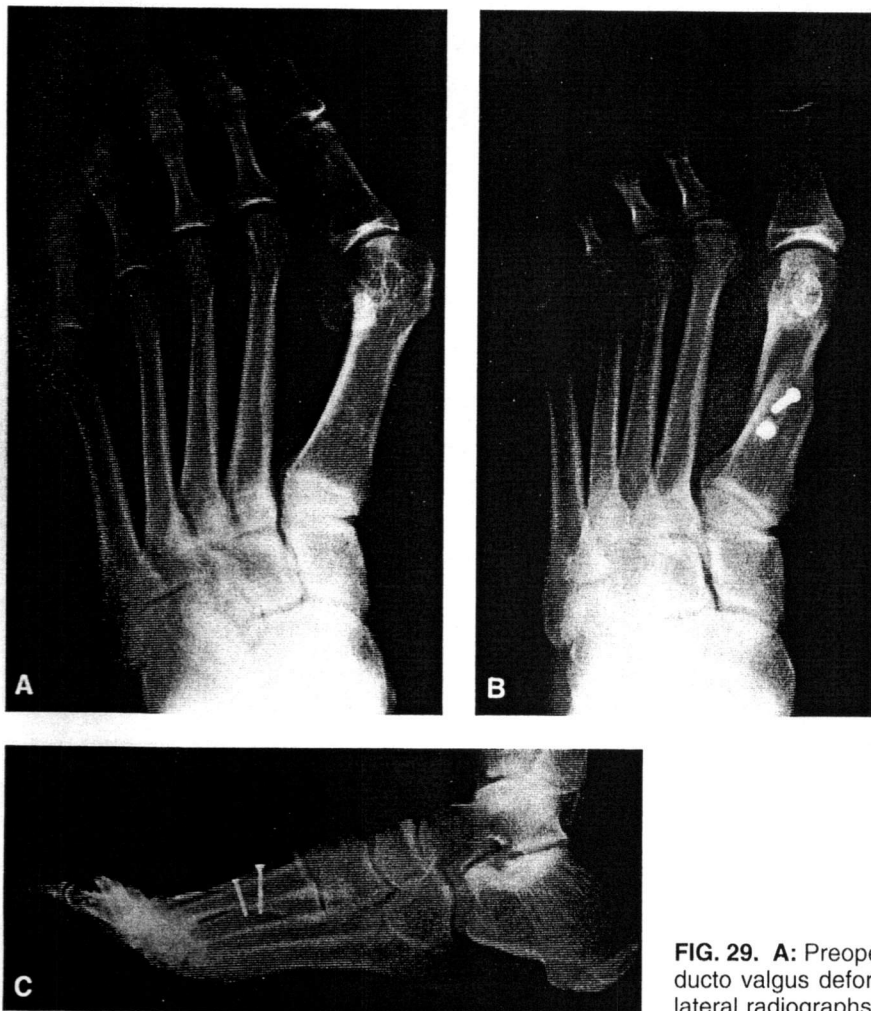

FIG. 29. **A:** Preoperative radiograph of a patient with hallux abducto valgus deformity. **B,C:** Postoperative dorsal plantar and lateral radiographs.

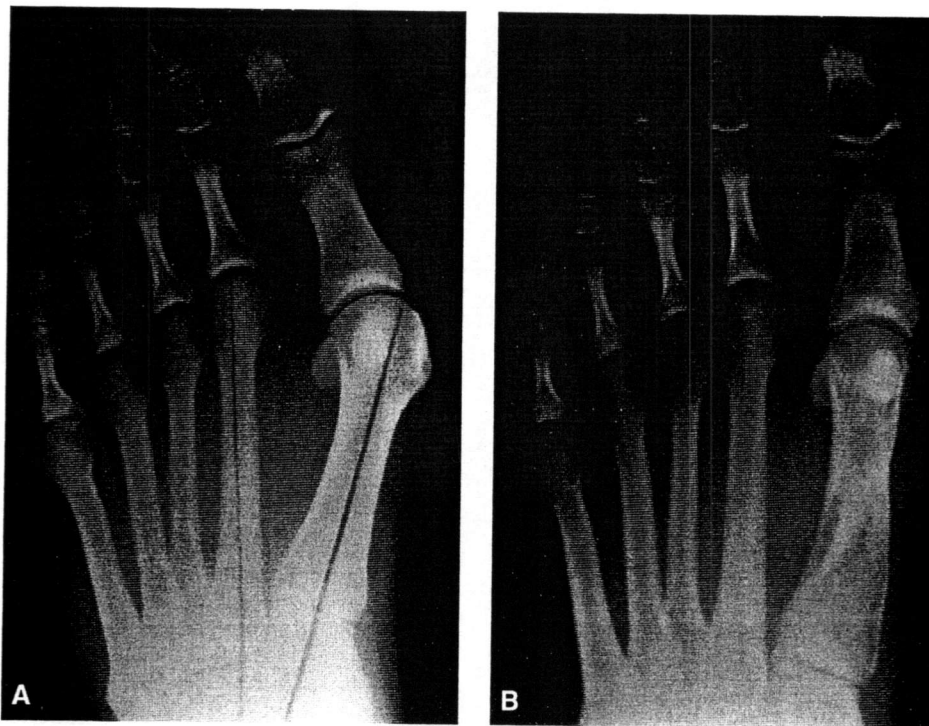


FIG. 30. Preoperative (A) postoperative (B) radiographs of a patient after a healed Mau osteotomy and after removal of fixation.

Ludloff Osteotomy

The dissection for the Ludloff procedure is the same as that for the Mau procedure. Once the patient's foot is positioned, the osteotomy is performed from medial to lateral with an orientation from dorsal proximal to plantar distal. The osteotomy extends from 1.5 cm distal to the metatarsocuneiform joint to proximal to the sesamoid apparatus. The distal fragment is transposed laterally to reduce the intermetatarsal angle. The osteotomy is stabilized with a bone clamp, and correction is evaluated before fixation. The osteotomy is fixated, and the medial overhang of bone is removed.

Modifications

As originally described, both the Mau and Ludloff procedures were shorter, midshaft osteotomies. Neese and colleagues introduced a longer modified Mau procedure, as just described (4). This makes good, stable, internal fixation easier and also tends to leave the osteotomy closer to parallel relative to the supporting surface, thereby enhancing later resistance to weight-bearing forces. This modification appears to be a preferred approach compared with the original procedure.

The Mau and Ludloff osteotomies are versatile procedures that allow additional adjustments to realign the first metatarsal in addition to reducing the intermetatarsal angle (Figs. 31 and 32). If the osteotomy is oriented from medial dorsal to lateral plantar, then plantarflexion can be achieved when the intermetatarsal angle is reduced. Conversely, if the osteotomy is oriented from medial plantar to lateral dorsal, then dorsiflexion will occur when the osteotomy is shifted. The distal fragments may be shifted distally or proximally, affecting the length of the metatarsal. If the longitudinal orientation of the osteotomy deviates from the weight-bearing surface, then translation in the proximal or distal direction may also affect the sagittal plane position of the first metatarsal. In the traditional orientation of the Ludloff procedure, if the metatarsal is shifted distally, then lengthening and plantarflexion will occur. With the Mau procedure, distal shift of the metatarsal produces lengthening and dorsiflexion. If each osteotomy is shifted proximally, then the reverse effects will be noted. However, if the plane of the osteotomy is perpendicular to the weight-bearing surface, then pure lengthening or shortening may be accomplished without any sagittal plane effect.

An abnormal proximal articular set angle may also be addressed with either procedure. With a Ludloff osteotomy, the distal segment may be swivelled medially to reduce the

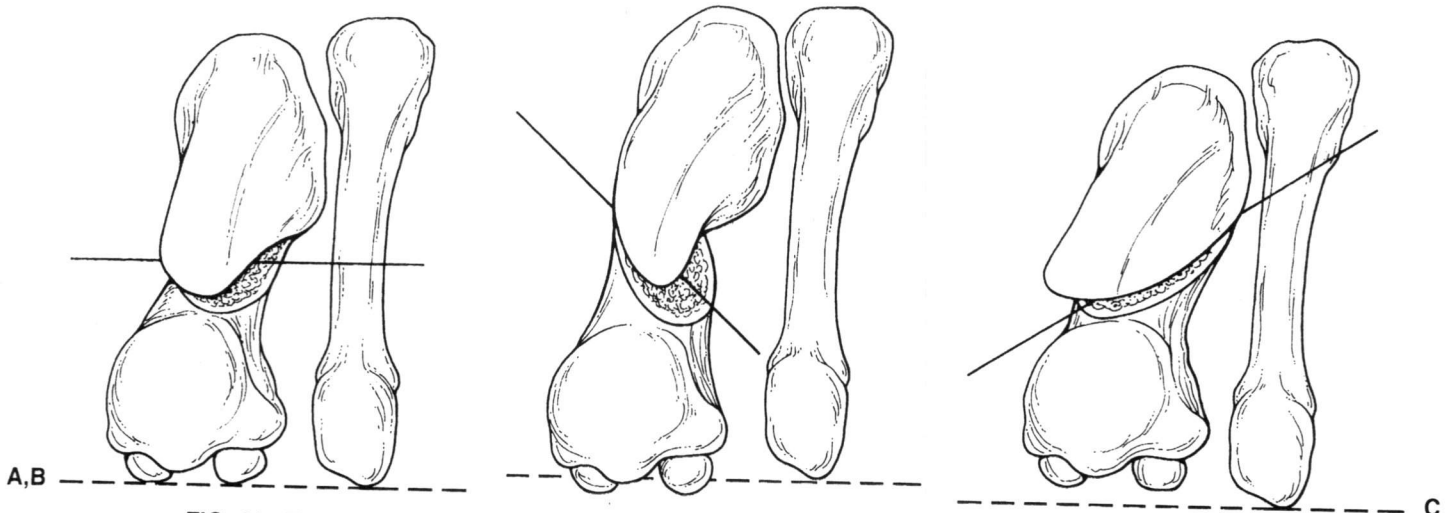


FIG. 31. The sagittal plane of the first metatarsal is influenced by the plane of the Mau osteotomy. **A:** If the plane of the osteotomy is close to parallel with the weight-bearing surface, then the metatarsal head will neither dorsiflex nor plantarflex with rotation. **B:** Orienting the plane of the osteotomy from dorsal medial to plantar lateral creates plantarflexion of the capital fragment with lateral movement. **C:** A plantar medial to dorsal lateral plane creates dorsiflexion with lateral movement of the capital fragment.

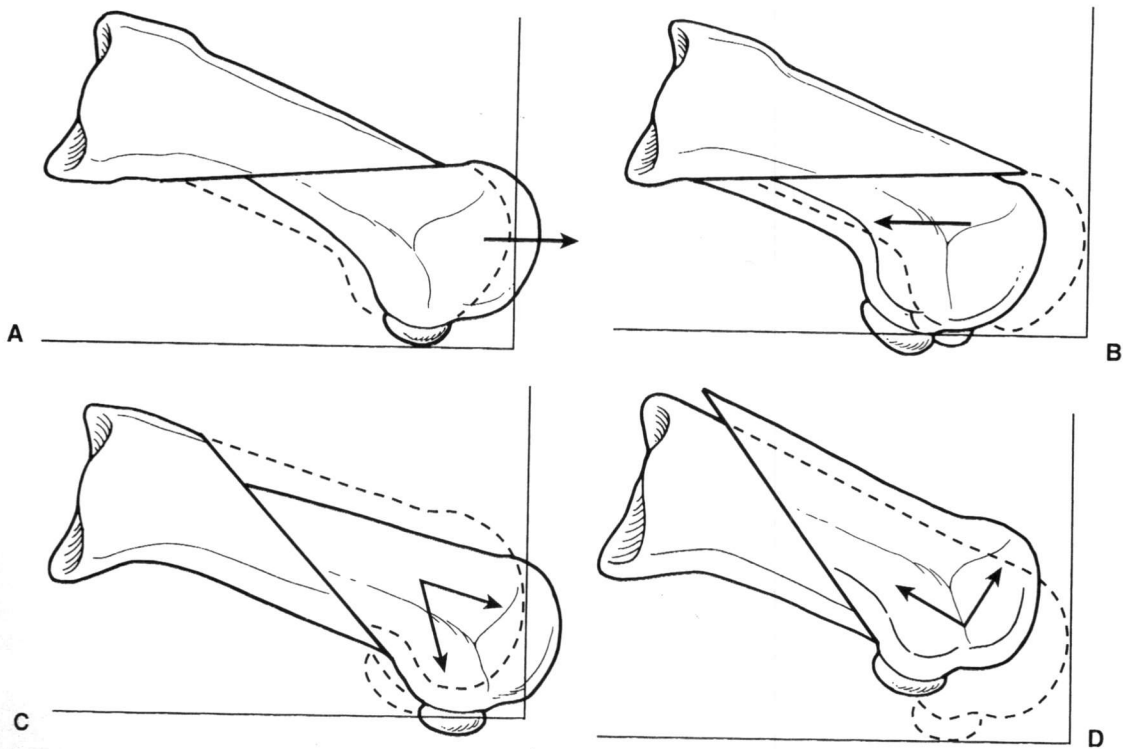


FIG. 32. When the Mau osteotomy is performed, sliding of the fragments distally or proximally influences the length of the first metatarsal. Little sagittal plane deviation will be noted if the osteotomy is oriented close to parallel with the weight-bearing surface. **A:** Mau osteotomy with the capital fragment distracted distally, thereby elongating the first metatarsal. **B:** Mau osteotomy with the capital fragment shifted proximally, thereby shortening the first metatarsal. **C:** Ludloff osteotomy with the capital fragment distracted distally. Note the elongation and plantarflexion of the first metatarsal. **D:** Ludloff osteotomy with the capital fragment shifted proximally. Note the shortening and dorsiflexion of the first metatarsal.

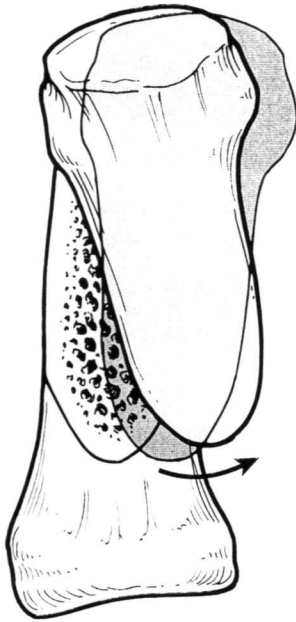


FIG. 33. Proximal articular set angle correction with the Ludloff osteotomy. After the fragment is transposed, the proximal segment is rotated laterally to shift the orientation of the articular surface.

proximal articular set angle. However, the amount of correction of the proximal articular angle that can be achieved is limited by the ultimate abutment of the proximal segment of the osteotomy against the second metatarsal. In addition, as more rotation is introduced to compensate for a deviated proximal articular set angle, the amount of available intermetatarsal angle correction is reduced (4) (Fig. 33). A larger deviation of the proximal articular set angle is more easily addressed with the Mau procedure in combination with a capital osteotomy such as the Reverdin procedure.

Fixation

Fixation of the Ludloff and Mau osteotomies is relatively easy. Two screws are preferred to prevent rotation and slippage. One of the screws is typically oriented perpendicular to the osteotomy. Cortical screws up to 3.5 mm are commonly employed (5,8,11), although 2.0-mm cortical screws have also been used successfully (4). The screws are positioned in the proximal and midpoint areas along the length of the osteotomy. If the screws are placed too far distally or proximally, then a stress riser of the dorsal or plantar cortices may occur. A third screw can be used if necessary and if the length of the osteotomy permits.

Postoperative Considerations

The postoperative course for both these procedures is varied. Immobilization in a non-weight-bearing cast

or splint has been used for periods ranging from 12 days to 6 weeks (4,5,13). Studies show that patients may be able to ambulate safely at 3 weeks postoperatively (5,6). Vogler recommended a slipper cast for 4 to 6 weeks (11).

RESULTS

Few reports in the English literature have documented the success achieved with either of these osteotomies. Neese et al. noted good results in 21 cases with the modified Mau procedure (4). The average intermetatarsal angle preoperatively measured 13.6 degrees and was reduced to an average of 4.38 degrees postoperatively. The average amount of first metatarsal shortening was 1.37 mm, with a range of 0.82 to 2.24 mm. Intermetatarsal angles up to 20 degrees were said to have been effectively addressed with the modified Mau osteotomy.

Bar-David and Greenberg noted 95% success in 22 cases of hallux abducto valgus in which the Mau procedure was used to repair the deformity (6). The average reduction in the intermetatarsal angle was 10.5 degrees. Eight patients had preoperative intermetatarsal angles measuring between 18 and 21 degrees. A Reverdin-Green procedure was employed in 18 of the cases to reduce the deviation in the proximal articular set angle.

Experiences with the Ludloff procedure were documented by Saxena and McCammon (5). In 14 cases, the average preoperative intermetatarsal angle of 15.9 degrees was reduced to 9.4 degrees. Patients were maintained non-weight bearing for 3 weeks and were allowed to ambulate with a surgical shoe for the next 2 to 3 weeks before they resumed wearing a tennis shoe. Complications consisted of a single delayed union, a patient with recurrent hallux abducto valgus deformity, and a patient with pain beneath the second metatarsal head.

Anecdotal experience has shown that the incidence of delayed bone healing is not increased in either of these procedures when rigid internal fixation is used. Complications encountered with these procedures may include fracture of the dorsal or plantar shelf. This may occur intraoperatively or when weight bearing begins. Therefore, patients who are allowed to bear weight before the osteotomy heals should be carefully monitored (Fig. 34). Elevation of the capital fragment can occur and may lead to lesser metatarsalgia, stress fracture of the lesser metatarsals, or hallux limitus.

The Mau-Ludloff shaft osteotomies are alternative procedures to first metatarsal basal procedures when addressing hallux abducto valgus deformity with high intermetatarsal angles. Outcomes are usually reliable, and complications are few. Problematic or delayed bone healing does not appear to be a concern.

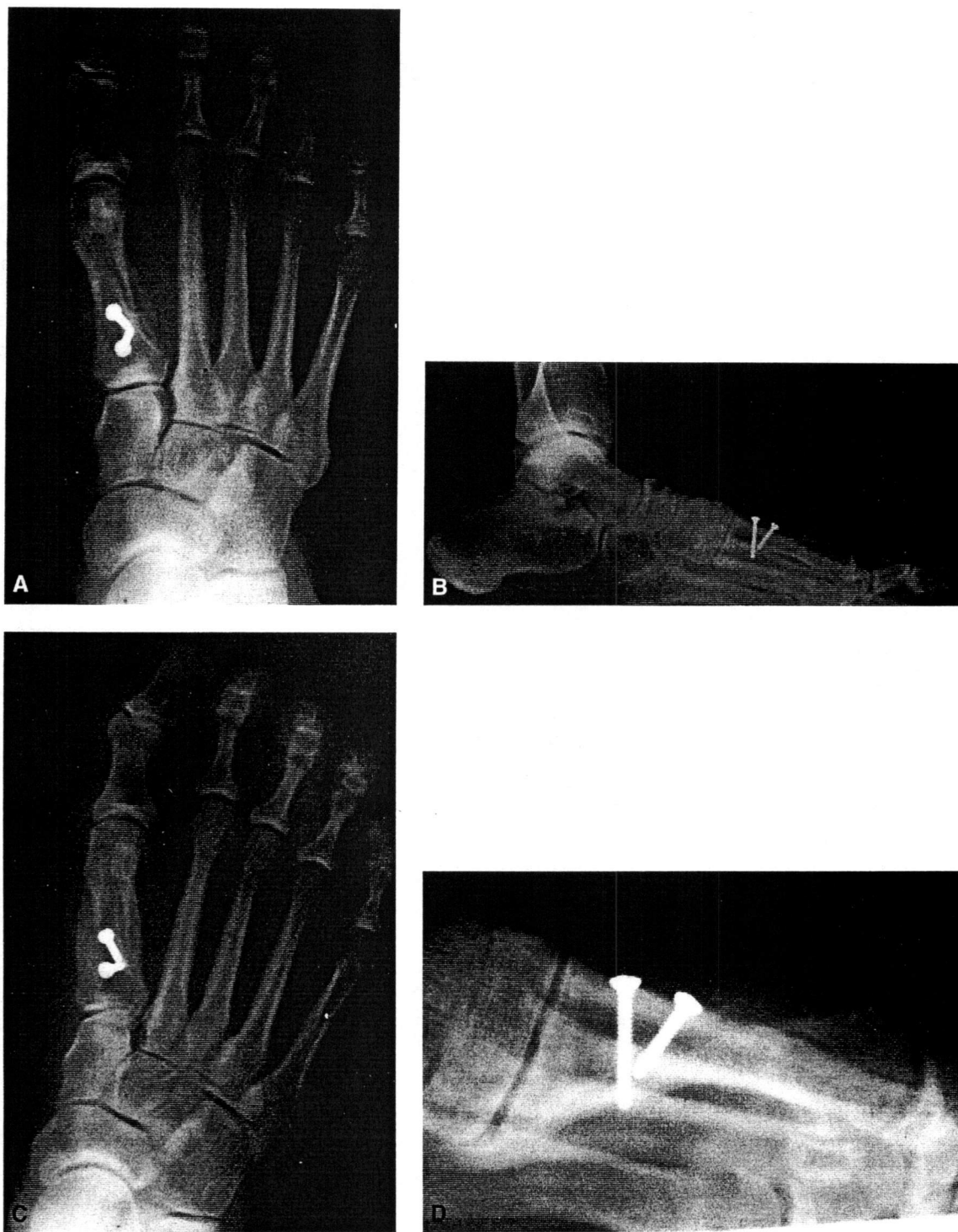

FIG. 34. A,B: Dorsal plantar and lateral radiographs, 6 weeks after Mau osteotomy, with the presence of a dorsal shelf fracture resulting from ground reaction forces. **C,D:** At 10 months postoperatively, note the complete healing and dorsiflexion of the capital fragment.

REFERENCES

1. Ludloff K. Hallux valgus operation. *Zentralbl Chir* 1913; 40:306.
2. Ludloff K. Die Beseitigung des hallux valgus durch die schräge plantardorsale Osteotomie des Metatarsus I. *Arch Klin Chir* 1918;110:364-387.
3. Mau C, Lauber HT. Die operative behandlung des hallux valgus (Nachuntersuchungen). *Dtsch Z Chir* 1926;197:361-375.
4. Neese DJ, Zelichowski JE, Patton GW. Mau osteotomy: an alternative procedure to the closing abductory base wedge osteotomy. *J Foot Surg* 1989;28:352-362.
5. Saxena A, McCammon D. The Ludloff osteotomy: a critical analysis. *J Foot Ankle Surg* 1997;36:100-105.
6. Bar-David T, Greenberg P. Retrospective analysis of the Mau osteotomy and effect of a fibular sesamoidectomy. *J Foot Ankle Surg* 1998; 37:212-216.
7. Martin DE, Blich EL. Alternatives to the closing base wedge osteotomy. *Clin Podiatr Med Surg* 1996;13:515-531.
8. Vogler HW, Smith ME. Osteotomy of the first metatarsal shaft in hallux abducto valgus surgery. In: McGlamry ED, Banks AS, Downey MS, eds. *Comprehensive textbook of foot surgery*, 2nd ed. Baltimore: Williams & Wilkins, 1992:523-532.
9. Ruch JA. Base wedge osteotomies of the first metatarsal. In: McGlamry ED, Banks AS, Downey MS, eds. *Comprehensive textbook of foot surgery*, 2nd ed. Baltimore: Williams & Wilkins, 1992:504-522.
10. Patton GW, Zelichowski JE. Middiaphyseal osteotomies. In: Hetherington VJ, ed. *Hallux valgus and forefoot surgery*. New York: Churchill Livingstone, 1994:215-225.
11. Vogler HW. Shaft osteotomies in hallux valgus reduction. *Clin Podiatr Med Surg* 1989;6:47-69.
12. Mizel MS. The role of the plantar first metatarsal first cuneiform ligament in weightbearing on the first metatarsal. *Foot Ankle* 1993;14: 82-84.
13. Cisar J, Holz U, Jenninger W, et al. Die Osteotomie nach Ludloff bei der hallux-valgus-Operation. *Aktuelle Traumatol* 1983;13:247-249.

SELECTED READING

- Blatter G, Magerl F. Osteotomien des ersten strahls zur Behandlung des Hallux valgus. *Ther Umsch* 1991;48:803-811.