

Retrospective Analysis of the Mau Osteotomy and Effect of a Fibular Sesamoidectomy

Tzvi Bar-David, DPM, and Paul M. Greenberg, DPM

The purpose of this study was to evaluate retrospectively outcomes of the Mau osteotomy for hallux abducto valgus deformity. Twenty-two patients were evaluated by the senior author on an average of 14 months (range, 3–34 months) following their surgery. Preoperative and postoperative intermetatarsal (IM) and hallux abductus (HA) angles were evaluated as well as range of motion of the first metatarsophalangeal joint and patient satisfaction. The mean preoperative IM and HA angles were 16.1° and 35.8°. The mean reduction in IM and HA angles was 10.5° and 23.5°, respectively. Joint range of motion was 58° of dorsiflexion (range, 42°–80°) and 11° of plantarflexion (range, 0°–20°). There were no cases of delayed healing or avascular necrosis. There were two patients (9%) with radiographic values consistent with hallux varus; however, neither patient had a clinical appearance of hallux varus and neither patient was displeased with the outcome. Ninety-one percent of patients returned to a soft shoe or sneakers in an average of 5.1 weeks following surgery. Eighty-two percent of patients had no pain at the time of their evaluation, and 96% of patients stated they were satisfied or very satisfied with the surgery. Comparing the subgroup of patients who underwent a Mau-Reverdin procedure with another subgroup undergoing a Mau-Reverdin fibular sesamoidectomy, there was a 3.7° greater reduction of IM angle and 6.7° greater reduction in HA angle in the subgroup with the fibular sesamoidectomy. (The Journal of Foot & Ankle Surgery 37(3):212–216, 1998)

Key words: bunionectomy, fibular sesamoidectomy, hallux abducto valgus, Mau osteotomy

Preoperative decision making for hallux abducto valgus surgery takes into consideration at least three parameters for realignment of the first metatarsophalangeal joint (MTPJ): 1) reduction of the metatarsus primus adductus (MPA), as measured by the intermetatarsal angle (IM); 2), evaluation of the distal articular cartilage of the first metatarsal, as measured by the proximal articular set angle (PASA) (1) and as is observed intraoperatively; and 3) soft-tissue balancing. The goal of soft-tissue balancing or interspace release is to complement the osseous correction to allow the MTPJ to become congruous. The metatarsal sesamoid articulation is an important part of MTPJ congruity. The radiographic measurement of the tibial sesamoid position can be helpful in assessing the degree of the interspace release which may be necessary. Although no one specific value will qualify removal of the fibular sesamoid, a position of 5 or greater will require sequential interspace release with potential removal of the sesamoid (1, 2). Consideration of all three of these

parameters will affect the ultimate success of a “bunionectionomy.” A proximal osteotomy may be necessary when the IM angle is greater than 15° or when correction of both the MPA and PASA is necessary (3). Basilar osteotomies have been the most common of these osteotomies. However, a prolonged postoperative immobilization period, elevated first ray, hallux limitus, and lesser metatarsalgia have all been documented as possible sequelae of these procedures (3–5). In recent years midshaft osteotomies have gained popularity. Procedures in this category include the Scarf or Z osteotomy (6), Offset-V osteotomy (7), and Ludloff (8) and Mau (9) osteotomies.

The Ludloff osteotomy is a midshaft osteotomy oriented from dorsal-proximal to plantar-distal. The Mau osteotomy took its origins as a modification of the Ludloff osteotomy in the early 20th century. The Ludloff osteotomy was not fixated and Mau challenged its inherent instability to ground reaction forces which would cause displacement of the dorsal fragment (Fig. 1). He described the reverse osteotomy, from dorsal-distal to plantar-proximal producing a dorsal shelf to resist the ground reaction forces. Most recently, this procedure was modified with a longer proximal cut entering the metaphyseal bone to allow fixation with compression screws (10). The purpose of this study was to describe results of the Mau osteotomy in combination with a distal

Private Practice, New York, NY. Address correspondence to: Tzvi Bar-David, DPM, 3616 Henry Hudson Parkway, Riverdale, NY 10463.

Received for publication December 1997; accepted in revised form for publication March 1998.

The Journal of Foot & Ankle Surgery 1067-2516/98/3703-0212\$4.00/0 Copyright © 1998 by the American College of Foot and Ankle Surgeons

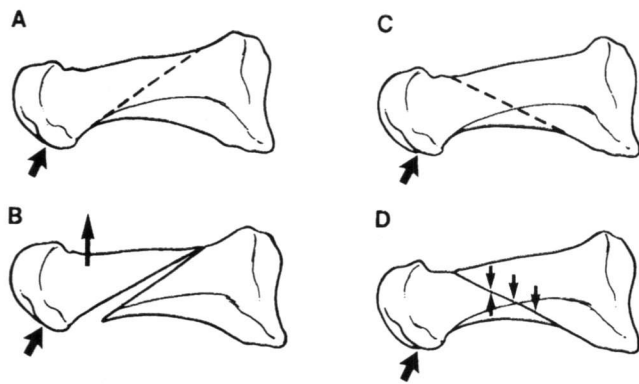


FIGURE 1 A, Ludloff osteotomy. B, Note dorsal displacement of the capital fragment with the Ludloff osteotomy in response to ground reaction forces. C, Mau osteotomy. D, Note the dorsal shelf of Mau osteotomy which prevents dorsal displacement of the capital fragment and promotes stability in response to ground reaction forces.

modified Reverdin-Green osteotomy (11, 12) with and without a fibular sesamoidectomy.

Materials and Methods

A retrospective review of the Mau osteotomy was conducted. Patients having undergone the procedure were asked to return to the office for completion of a questionnaire (Fig. 2), an examination of the operative foot, and follow-up radiographs. All patients contacted were from the authors' private practice. Author T.B.-D. was present at all procedures. Seventeen patients responded representing 22 feet. Five patients had bilateral surgery with at least 6 months between each foot. Twelve patients underwent the procedure on only one foot. None of the patients had previous surgery

1. How long after surgery were you able to wear a soft shoe or sneaker? 3 wks 4 wks 5 wks 6 wks 7 wks 8 wks >8 wks
2. How satisfied are you with the surgery? very dissatisfied dissatisfied satisfied very satisfied
3. Would you undergo this procedure again? If no, why not? Yes ___ No ___
4. Would you recommend this procedure to others with a similar problem to yours? Yes ___ No ___
5. How long after surgery did you not have any pain related to the surgery? 1 month 2 months 3 months 4 months 5 months 6 months 1 year Pain still present

FIGURE 2 Mau follow-up study patient questionnaire.

of the first metatarsophalangeal joint. Radiographic measurements of the preoperative IM angle and hallux abductus (HA) angle were compared to the postoperative follow-up value of each. Elevation of the first metatarsal was not radiographically assessed, but rather first metatarsophalangeal joint function was measured by hallux dorsiflexion and plantarflexion measured to the long axis of the metatarsal with a goniometer. Documentation for the presence of metatarsalgia postoperatively was also made.

The operative technique is performed as follows. A dorsal linear incision, the length of the first metatarsal, is performed medial and parallel to the extensor hallucis longus tendon. The incision is deepened to periosteum and capsule, where an inverted L capsulotomy is performed. The periosteal incision is extended proximally to approximately 1.0 cm distal to the metatarsal-cuneiform joint. Capsule and full-thickness periosteum are reflected dorsally and plantarly. The plantar flare of the base of the metatarsal is visualized (Fig. 3). The distal articular cartilage is inspected for lateral deviation, which is correlated with PASA.

An incremental first interspace release, consisting of release of the adductor hallucis tendon, release of the fibular sesamoid metatarsal suspensory ligament, release of the deep transverse intermetatarsal ligament, lateral capsulotomy, and, if necessary, a fibular sesamoidectomy, is performed (2). The release is performed dorsally through the original skin incision. The medial exostosis is removed and the foot is positioned on its lateral aspect so the dorsal, medial, and plantar surfaces of the midshaft of the metatarsal are visualized. Care is taken to avoid extensive dissection on the dorsal and lateral aspects of the metatarsal head. A power saw (most often sagittal) is used to perform the osteotomy which is oriented from distal dorsal to proximal plantar. Distally it begins approximately 1-1.5 cm proximal to the metatarsophalangeal joint and proximally it ends approximately 1-1.5 cm distal to the metatarsal-cuneiform joint (Fig. 4).

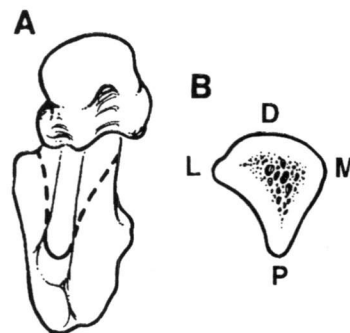


FIGURE 3 A, Plantar view of the first metatarsal. B, Note triangular shape with plantar apex (P).



FIGURE 4 Medial view of the Mau osteotomy.

The osteotomy is stabilized with a bone clamp and a 0.045-inch Kirschner wire is drilled perpendicular to the osteotomy from dorsal to plantar just distal to the end of the plantar cut. The purpose of the wire is to act as a pivotal rotation axis. Once the Kirschner wire is inserted, the bone clamp is removed and the plantar shelf is rotated laterally on the dorsal shelf to reduce the IM angle. We stress that this is a rotational osteotomy and not a transpositional one. Hence the plantar fragment is rotated and not displaced. Proximal to the Kirschner wire there is almost full bony contact between the fragments. The bone clamp is now reapplied to stabilize the osteotomy in its corrected position.

IM angle reduction is evaluated prior to fixation by visual inspection and palpation of the first interspace to determine the distance between the first and second metatarsal heads. If under correction or overcorrection is deemed to have occurred, then the bone clamp may be removed and proper correction achieved.

Fixation is accomplished with two 2.0-mm cortical lag screws. The screws are oriented perpendicular to the osteotomy and positioned in the proximal and midpoint areas along the length of the bone cut. If the screws are placed too far distal or proximal, then a stress riser of the dorsal or plantar cortices may occur. A third screw can be used if necessary. The redundant medial bone is removed with a power burr.

If the distal articular cartilage requires realignment, a Reverdin-Green osteotomy is performed. While we measure the PASA preoperatively, clinically significant articular deviation of the distal cartilage of the first metatarsal head remains a qualitative intraoperative assessment. The osteotomy is most often not fixated since a lateral cortical hinge remains intact and the patient is immobilized. The surgical site is closed in layers. The foot is immobilized in a posterior splint and the patient is nonweightbearing on the operative foot for 3–4 weeks. Once the posterior splint is removed, the patient is allowed to ambulate in a sneaker or soft shoe.

Results

Nine feet (40.9%) underwent the Mau with a Reverdin-Green osteotomy. Four feet (18.2%) underwent the Mau with a fibular sesamoidectomy. Nine feet (40.9%)

underwent the Mau with both a Reverdin-Green and fibular Sesamoidectomy (Table 1).

The average age at the time of surgery was 43 years with a range of 20–63 years. The average time of postoperative evaluation was 14 months with a range of 3–34 months. The average preoperative IM and HA angles were 16.1° (range, 10°–21°) and 35.8° (range, 20°–55°). The average postoperative IM and HA angles were 5.6° (range, 0°–12°) and 12.3° (range, 8°–35°). The average IM and HA angle reduction was 10.5° (range, 4°–19°) and 23.5° (range, 8°–35°).

In response to the patients' subjective questionnaire, 9% (2/22) stated it took more than 8 weeks to ambulate in a soft shoe or sneaker. Ninety-one percent (20/22) returned to ambulation in a soft shoe or sneaker at an average of 5.1 weeks postoperatively. Eighteen percent (4/22) stated they had some surgical or postsurgical related pain at the time of follow-up. Eighty-two percent (18/22) had complete resolution of any pain related to the surgery at an average of 2.5 months postoperatively. Five percent (1/22) stated they were dissatisfied with the result. Ninety-six percent were either satisfied or very satisfied. Ninety-one percent (20/22) would undergo the procedure again and 9% (2/22) would not. Ninety-six percent would recommend the procedure to a friend with a similar problem and 5% (1/22) would not.

On physical examination two patients (9%) experienced metatarsalgia. One of these patients also had stress fractures of the second and third metatarsals and was the patient who was dissatisfied. The other 20 operated feet experienced no lesser metatarsalgia. The postoperative dorsiflexion of the first metatarsophalangeal joint averaged 58° with a range of 42°–80°. Postoperative plantarflexion averaged 11° with a range of 0°–20°. There were no cases of delayed bone healing. Additional complications related to the surgery included a stress fracture of the dorsal shelf in one patient, which occurred at the start of ambulation. Another patient had a stress fracture of the plantar shelf also when beginning to ambulate. Both were treated with a soft shoe and compressive dressing for 3 weeks. Although two patients had a negative HA angle postoperatively, neither had a clinical hallux varus deformity.

Discussion

The results obtained in this study are similar to those documented by others. Patton achieved an average of 9.3° reduction in the IM angle with the Mau osteotomy (10). Saxena documented ambulating his patients at 3 weeks postoperatively with the Ludloff osteotomy (13). These correlate with our results and postoperative course.

Every osteotomy has its own inherent advantages and disadvantages. Ultimately, the preference of any osteotomy will be dependent upon its technical ease of

TABLE 1 Patient data

Patient	Procedure	Age	F/U (months)	Preop IM	Preop HA	Preop PASA	Preop TSP	Postop IM	Postop HA	Change IM	Change HA	Postop PASA	Postop DF	Postop PF
1	M,F	38	9	13	30	25	6	8	15	5	15	20	50	5
2	M,F	42	31	13	25	23	6	0	-5	13	30	-5	70	12
3	M,F	55	22	13	20	15	6	0	-12	13	32	-13	46	14
4	M,F	56	8	19	35	26	7	0	8	19	27	0	42	12
5	M,R	50	34	14	28	30	6	10	20	4	8	5	80	10
6	M,R	51	28	15	25	25	6	5	0	10	25	15	70	10
7	M,R	30	4	20	38	32	5	7	13	13	25	4	57	9
8	M,R	21	25	18	45	37	Ab	10	20	8	25	4	60	12
9	M,R	48	21	16	36	28	5	7	7	9	29	0	70	10
10	M,R	59	12	20	46	27	7	12	20	8	26	17	50	12
11	M,R	43	7	16	45	28	6	5	30	11	15	20	55	10
12	M,R	34	13	15	30	20	6	10	17	5	13	5	70	10
13	M,R	48	5	13	25	15	5	7	15	6	10	15	45	15
14	M,R,F	30	4	19	55	40	6	2	20	17	35	5	60	15
15	M,R,F	29	12	16	32	39	5	0	10	16	22	0	60	15
16	M,R,F	20	12	19	40	35	5	5	20	14	20	15	55	12
17	M,R,F	21	3	15	44	40	6	1	20	14	24	25	70	15
18	M,R,F	63	4	15	33	28	7	10	15	5	18	8	40	10
19	M,R,F	41	7	10	33	28	5	5	0	5	33	4	40	10
20	M,R,F	60	33	16	40	38	6	5	10	11	30	10	70	30
21	M,R,F	62	5	21	48	33	6	8	13	13	35	10	65	0
22	M,R,F	50	10	19	35	26	7	7	15	12	20	8	55	5
Min.		20	3	10	20	15	5	0	-12	4	8	-13	42	0
Max.		63	34	21	55	40	7	12	30	19	35	25	80	30
Mean		43.2	14.1	16.1	35.8	29.0	5.9	5.6	12.3	10.5	23.5	7.8	58.2	11.5
SD		13.8	10.4	2.9	8.9	7.3	0.7	3.8	9.7	4.3	7.9	9.0	11.5	5.5

M, Mau; R, Reverdin; F, fibular sesamoidectomy; IM, intermetatarsal; HA, hallux abductus; PASA, proximal articular set angle; TSP, tibial sesamoid position; DF, dorsiflexion; PF, plantarflexion; Ab, congenitally absent tibial sesamoid; SD, standard deviation.

performance, the postoperative course, and the expected sequelae. Based upon this, the Mau midshaft osteotomy is a favorable procedure when capital osteotomies are not sufficient to achieve correction of the metatarsus primus adductus. A question which remains is what is the end range of IM angle correction which can be effectively addressed with the Mau osteotomy? The sample size of this study is not large enough to conclude any definitive ranges. However, within the total group ($N = 22$) there were eight patients with preoperative IM angle ranges from 18° to 21° . This subgroup achieved an average IM angle reduction of 13° . As stressed earlier, the authors also consistently perform the Mau osteotomy in combination with a Reverdin osteotomy and soft-tissue release, including fibular sesamoidectomy. It is the combination of these procedures that will determine the radiographic and clinical result achieved.

An attempt was made to isolate the radiographic effect of a fibular sesamoidectomy. To this end, within this small sample population, the authors compared the outcomes of the subgroups. One underwent Mau and Reverdin osteotomies with a fibular sesamoidectomy and the other only Mau and Reverdin osteotomies. Hence, the only difference between the two groups from a procedural standpoint was the removal of the fibular sesamoid. By

coincidence there were nine patients in each subgroup. The average preoperative IM and HA angles were 16.3° and 36.4° , respectively, in the Mau-Reverdin group, and 16.6° and 40° respectively, in the Mau-Reverdin fibular sesamoidectomy group. Utilizing a two-tailed p value, it was established that the differences were not statistically significant from one another (Table 2). Hence the groups can be compared. It was also difficult to speculate retrospectively how the decision was made to perform a fibular sesamoidectomy in one group and not the other with the almost-identical preoperative radiographic values.

TABLE 2 Comparison of Mau-Reverdin (MR) and Mau-Reverdin fibular sesamoidectomy (MRF) groups preoperatively

Group	Mean	SD	n	t	df	p
IM						
MR	16.3	2.5	9	0.2	(1,16)	.81
MRF	16.7	3.3	9			
HA						
MR	35.3	8.7	9	1.2	(1,16)	.25
MRF	40.0	7.8	9			

The p value which was greater than .05 indicates that each treatment group, MR and MRF, was not significantly different from the other.

TABLE 3 Comparison of MR and MRF treatment groups postoperatively with respect to change in IM and HA

Group	Mean	SD	n	t	df	p
IM change						
MR	8.2	2.9	9	2.1	(1,16)	.03
MRF	11.9	4.3	9			
HA change						
MR	19.6	8.0	9	1.9	(1,16)	.04
MRF	26.3	6.9	9			

The two *t*-tests reveal a *p* value being less than .05, which shows the results to be statistically significant.

Most interesting was the degree of correction achieved for the groups. The Mau-Reverdin group achieved an average reduction of 8.2° and 19.6° in the IM and HA. The Mau-Reverdin-fibular sesamoidectomy group achieved an average reduction of 11.9° and 26.3° in the IM and HA angles. In other words, there was 3.7° greater reduction in the IM angle and 6.7° greater reduction in the HA angle for the Mau-Reverdin fibular sesamoidectomy group. Utilizing the one-tailed *p* value, this was found to be statistically significant (Table 3). This demonstrates the effect of the fibular sesamoidectomy.

This article is not promoting a fibular sesamoidectomy nor is it asserting criteria for its indications. Nevertheless, it is important to validate that a fibular sesamoidectomy can help balance and realign the more severe cases of hallux valgus deformity. In the preoperative assessments, the authors attempt to outline all the components of the surgery and the procedure that will be used to address each component and its possible sequelae.

Conclusion

The Mau osteotomy is effective in reducing the metatarsus primus adductus component of hallux valgus deformity. This procedure can be used in lieu of a base-wedge osteotomy. A Reverdin osteotomy can be performed concomitantly with a Mau osteotomy

without concern for slower bone healing. A fibular sesamoidectomy is also sometimes utilized in combination with the Mau osteotomy with or without a Reverdin and can add to the overall correction achieved.

References

1. Haas, M. Radiographic and biomechanical considerations of bunion surgery, ch 2. In *Textbook of Bunion Surgery*, p. 40, edited by J. Gerbert, Futura Publishing, Mt. Kisco, NY, 1981.
2. Gudas, C. J., Greenberg, P. M., Pearson, W. K., Zenker, C. C., Azzolini, T. J., Marcinko, D. E. General principles of hallux abducto valgus reconstruction, ch 2. In *Comprehensive Textbook of Hallux Abducto Valgus Reconstruction*, pp. 19-61, edited by D. E. Marcinko, Mosby Year Book, St. Louis, 1992.
3. Bar-David, T., Trepal, M. J. A retrospective analysis of distal chevron and basilar osteotomies of the first metatarsal for correction of intermetatarsal angles in the range of 13 to 16 degrees. *J. Foot Surg.* 30:450-456, 1991.
4. Schubert, J. M., Reilly, C. H., Gudas, C. J. The closing wedge osteotomy. A critical analysis of first metatarsal elevation. *J. Am Podiatr. Assoc.* 74:13-24, 1984.
5. Zlotoff, H. Shortening of the first metatarsal following osteotomy and its clinical significance. *J. Am Podiatry Assoc.* 67:412-426, 1977.
6. Meyer, M. Eine neue modifikation der hallux valgus operation. *Zbl Chir* 53:3215-3268, 1926.
7. Vogler, H. W. Shaft osteotomies in hallux valgus reduction. In *Clinics in Podiatric Medicine and Surgery*, vol. 6, pp. 47-69, edited by K. T. Jules, W. B. Saunders Co., Philadelphia, 1989.
8. Ludloff, K. Die Beseitigung des Hallux valgus durch die schräge planta-dorsale Osteotomie des Metatarsus I. *Arch Klin Chir.* 110:364-387, 1918.
9. Mau, C., Lauber, H. T. Die operative Behandlung des Hallux Valgus (Nachuntersuchungen). *Dtsch. Z. Chir.* 197:363-375, 1926.
10. Neese, D. J., Zelichowski, J. E., Patton, G. W. Mau osteotomy: an alternative procedure to the closing abductory base wedge osteotomy. *J. Foot Surg.* 28:352-362, 1989.
11. Reverdin, J. Anatomic et operation de L'hallux valgus. *Int Med. Cong.* 2:408, 1881.
12. Todd, W. F. Osteotomies of the first metatarsal head: Reverdin, Reverdin modifications, Peabody, Mitchell, and DRATO, ch 8. In *Textbook of Bunion Surgery*, pp. 165-175, edited by J. Gerbert, Futura Publishing, Mt. Kisco, NY, 1981.
13. Saxena, A., McCammon, D. The Ludloff osteotomy: a critical analysis. *J. Foot Ankle Surg.* 36:100-105, 1997.